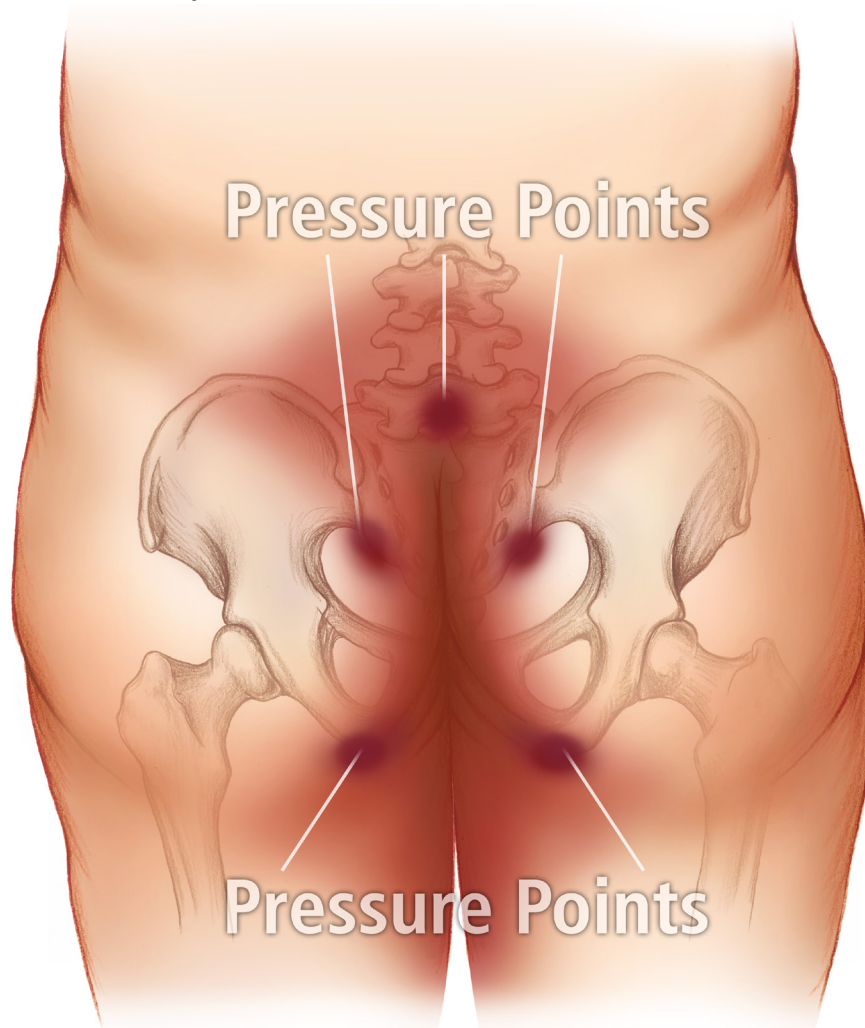


# Anatomic Locations of Pressure Ulcers

1. Sacrum	36.9%	6. Trochanter (hip bone)	5.1%
2. Heel	30.3%	7. Knee	3.0%
3. Ischium (sit bone)	8.0%	8. Scapula (shoulder blade)	2.4%
4. Elbow	6.9%	9. Occiput	1.3%
5. Malleolus (ankle bone)	6.1%		



Reference: Stephanie Amlung, PhD, RN; Wendy L. Miller, and Linda M Bosley, BSM "The 1999 National Pressure Ulcer Prevalence Survey: A Benchmarking Approach," *Advances in Skin & Wound Care*; 14(6):297-301, Nov-Dec 2001.